Ma questa ecografia delle anche è fatta bene?

Verifichiamolo insieme in pochi passaggi!

3 requisiti minimi

REFERTO ADEGUATO

Deve descrivere *almeno*:
- ✓ **tipo di Graf** (1a, 1b, 2a, 2b, ecc)
- ✓ **angoli** Alfa/Beta
- ✓ **conformazione** (tetto osseo, labrum, ecc)

NO?

REFERTO CONGRUENTE

Tipo di Graf e angoli *devono corrispondere*:
- ✓ **1a/1b** → Alfa ≥ 60°, qualsiasi età
- ✓ **2a/a+/a-** → Alfa 50-59°, età < 3mesi
- ✓ **2b** → Alfa 50-59°, età >3 mesi.....

NO?

IMMAGINI ALLEGATE

Deve includere *almeno*:
- ✓ 2 immagini per ogni lato (1 con misure di angoli, 1 senza)

NO?

5 punti per capire ABCD

1

RUOTA immagine:
- ✓parte **chiara a sinistra**
- ✓verticale **A in alto**

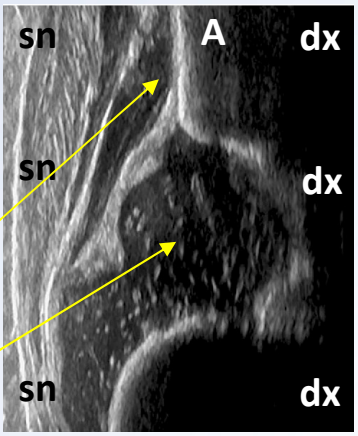

sn= a sinistra: parte **chiara** con **linee verticali** (superficiale)

dx= a destra parte **scura** (profonda)

- ✓Se **digitale**: ruota così
- ✓Se **cartaceo**, potresti trovare immagine ribaltata dx-sn, ma **tieni verticale A in alto**

2

Cerca **PALLA di NATALE F e cordino verticale A**

F =testa femore

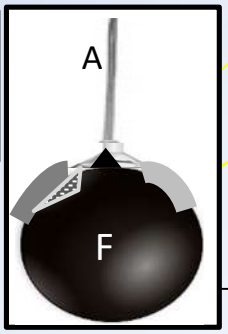

- ✓ Zona **rotondeggiante** scura
- ✓ Delimitata a dx, sin e in alto
- ✓ **Meno delimitata in basso**

Tutta scura, ma può anche avere:
- ✓ **puntini bianchi**
- ✓ **zona chiara** al centro

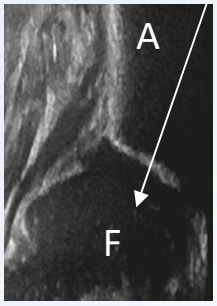

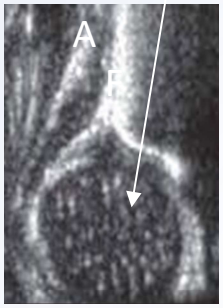

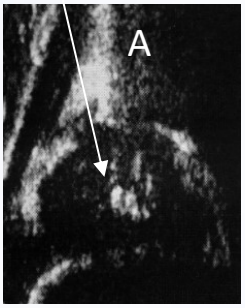

Non la trovi?

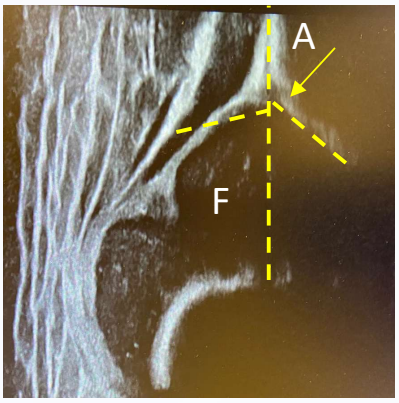

Prendi **immagine con le linee**:
- ✓ Linea **verticale** è **in asse con A**
- ✓ **Incrocio** linee=parte bassa **di A**

ORTOPEDIATRIA

3

Il **supporto** della palla di Natale **F** ha:
- ✓ **un cordino** verticale **A**
- ✓ **2 bracci (B/C)**

B→ profondo (vs zona scura)
C→ superficiale (vs zona chiara), un pò **ingrossato**

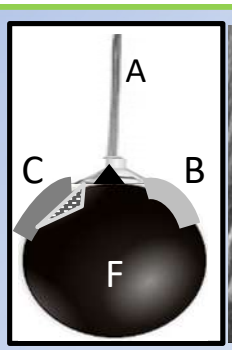

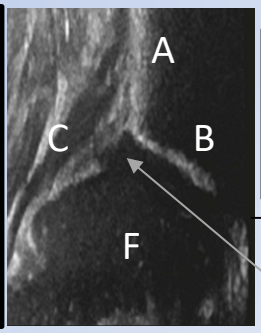

Non li trovi?
Le due **linee oblique** per le misure sono **in asse** coi **bracci B e C**

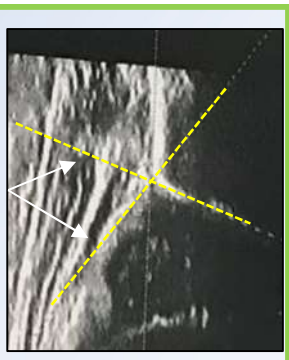

Triangolo nero **(T)** centrale **alla fine di A**

4

Braccio C ha **ispessimento** triangolare L (=Labrum)
- ✓ nella parte **attaccata a F**
- ✓ **a sinistra** di **triangolo T**

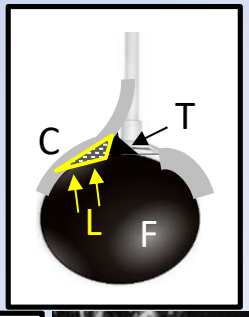

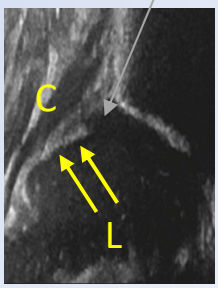

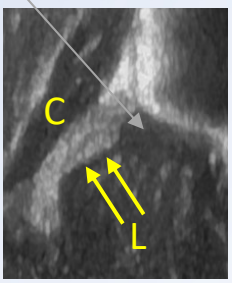

5

Sotto la palla F c'è **GANCIO D** (=metafisi femore)



- ✓ **Arco chiaro**
- ✓ **convesso vs sinistra** (=vs superficie)

Normali o no?

F è al centro di A
al max + profonda

Fondamentale: Supporto A+B

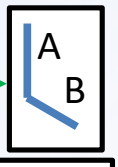

ANGOLO ALFA= tra linee tangenti a A e B

Anche NORMALI

Anche PATOLOGICHE

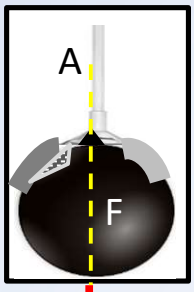

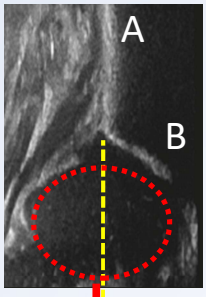

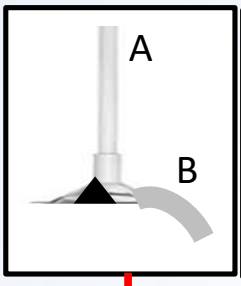

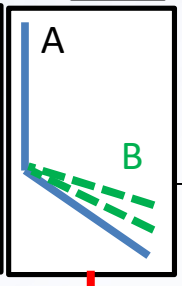

Normale è 60° o maggiore
(+ orizzontale)

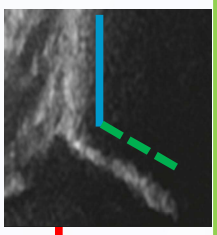

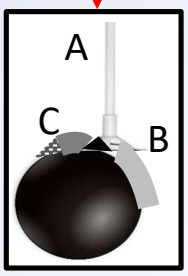

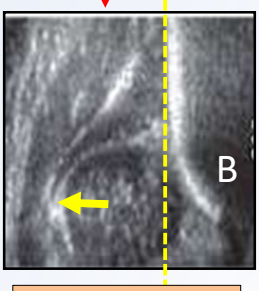

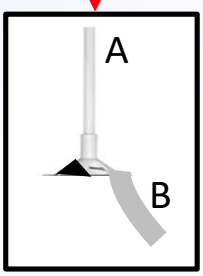

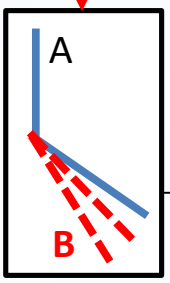

Patologico è <60°
(+ obliquo)

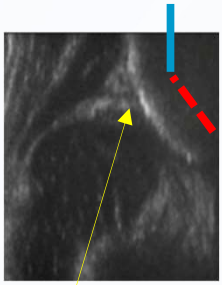

Supporto B «cede»

F si sposta **vs superficie**

B + **obliquo** e **convesso**

lo **spigolo tra A e B** è smusso

ORTOPEDIATRIA

ABCD per trovare gli errori

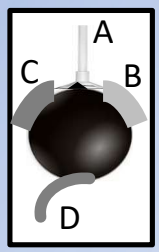

Valuta per ogni immagine A-B-C-D:
Rispondono ai requisiti?

NO? → **SCARTA QUESTE IMMAGINI! ***

*Solo in caso di lussazione ABCD potrebbero non vedersi insieme

A

- ✓ **è verticale?**
- ✓ **è ben definita?**
- ✓ la linea tangente è pressochè **verticale?**

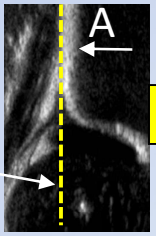

NO?

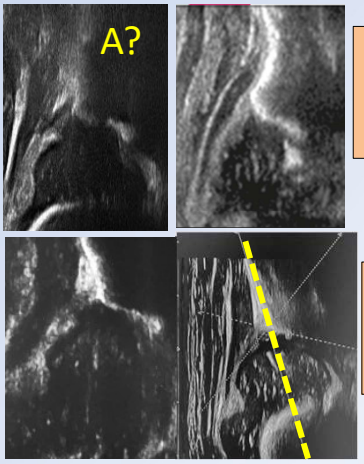

Mal definita, curva

Obliqua vs alto o vs basso

Errore molto frequente!

B

È ben definito?

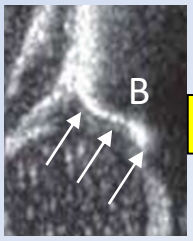

NO?

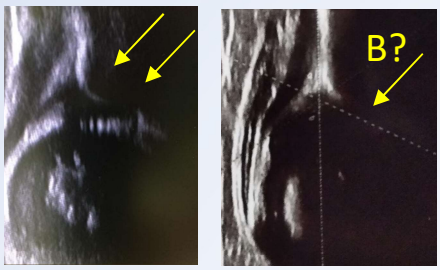

C

Contiene **ispessimento L?**

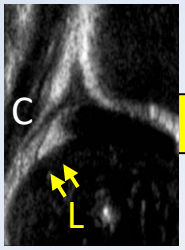

NO?

Serve un pò di **esperienza** per riconoscere L

D

È presente?

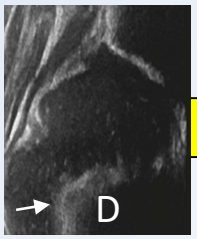

NO?

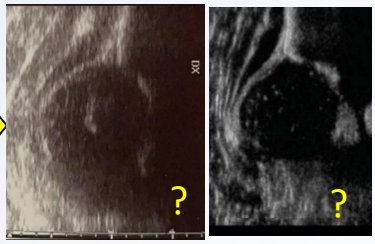

Errore molto frequente!

Scarta immagini **non valide** → **In caso di**

- ✓ **Mancanza di immagini valide**
- ✓ **Dubbi significativi** su linee **ABCD**
- ✓ **Referto** inadeguato/incongruente

→ Invio verso **ecografisti esperti in DEA**

OrtoPediatria, *Centro Spec. per la Displasia delle anche*

www.OrtoPediatria.org

© Tutti i diritti riservati - Bibliografia e fonti sul sito